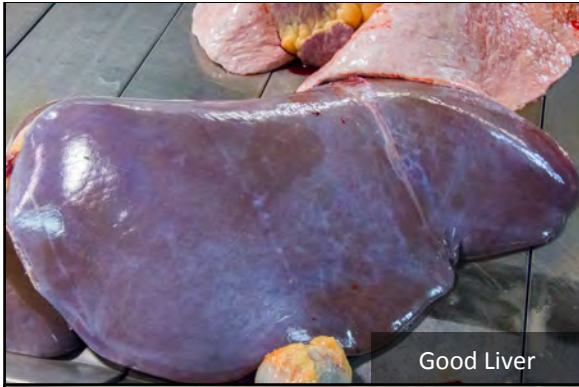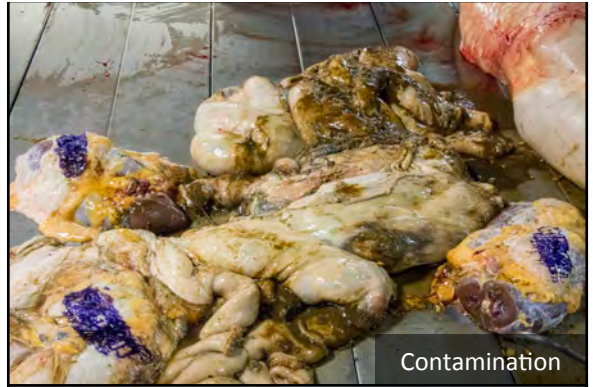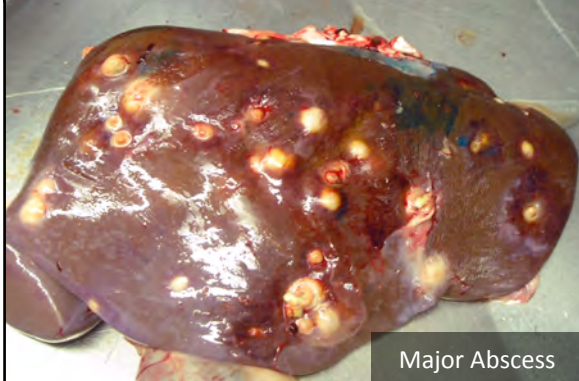




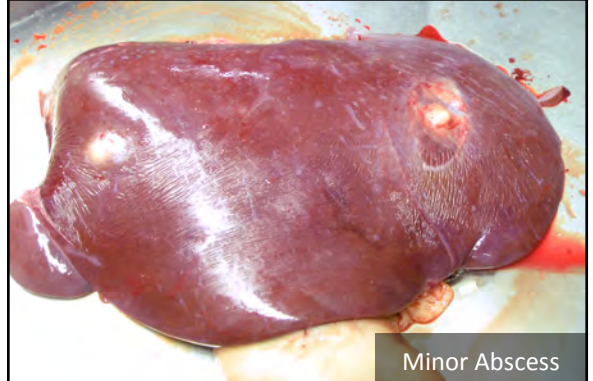
Good Liver



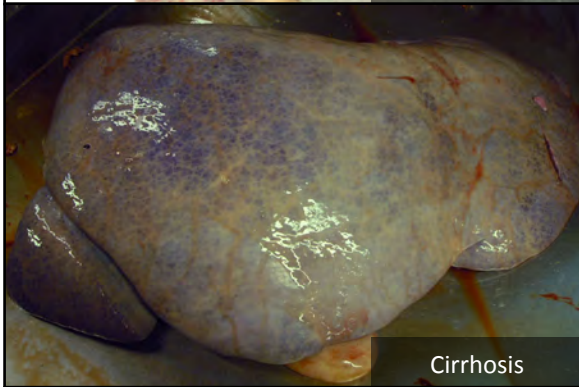
Contamination



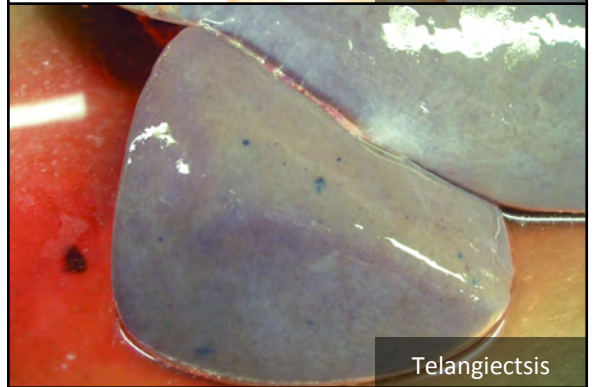Major Abscess



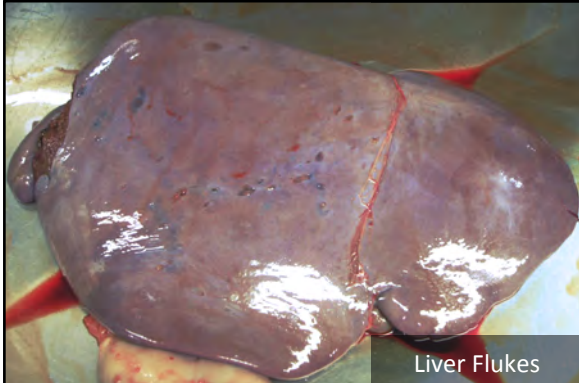
Minor Abscess



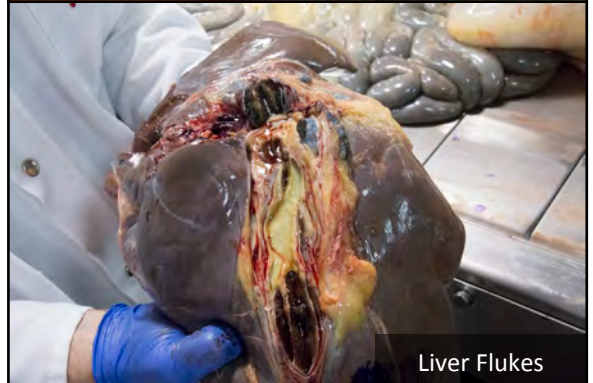Cirrhosis



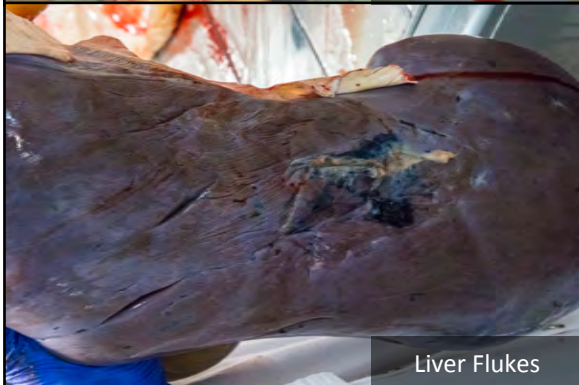Telangiectasis



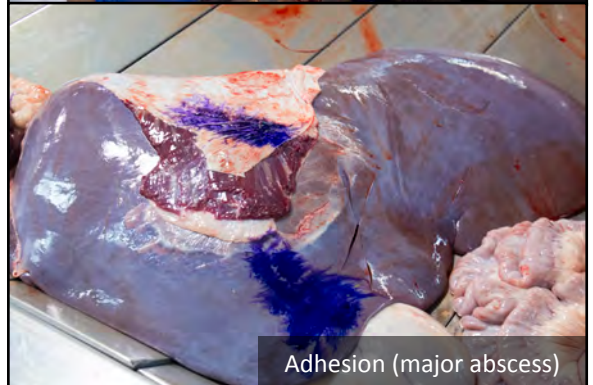
Liver Flukes



Liver Flukes



Liver Flukes



Adhesion (major abscess)